

Surgery in adults with tethered cord syndrome: outcome study with independent clinical review

REDMER VAN LEEUWEN, M.D., NICOLETTE C. NOTERMANS, M.D., PH.D.,
AND W. PETER VANDERTOP, M.D., PH.D.

*Department of Neurosurgery, University Hospital Vrije Universiteit, Amsterdam;
and Department of Neurology, University Hospital Utrecht, Utrecht, The Netherlands*

Object. The authors conducted a study to evaluate the risks and short-term benefits of surgical treatment for tethered cord syndrome (TCS) in patients older than 18 years of age.

Methods. The authors studied a series of 57 consecutive adult patients with TCS of varying origins. Patients were examined by the same neurologist in a standardized fashion before and after surgery, and most were followed for at least 2 years postoperatively.

Patient age ranged from 19 to 75 years. The mean age at onset of symptoms and diagnosis was 30 years and 37 years, respectively. Muscle strength improved (15 cases) or showed no change postoperatively (38 cases) in a large majority of patients (93%). In four patients a minor decrease in muscle strength was demonstrated, and there was significant deterioration in two (3.5%). In the two latter patients, a rapid decline in motor function was present preoperatively. Subjective assessment of pain, gait, sensory function, and bladder/bowel function at 4 weeks, 6 months, and 2 years postsurgery revealed improvement in a substantial percentage of patients. No major surgery-related complications occurred.

Conclusions. This is the largest series to date in which adult patients with TCS comprise the report. Untethering procedures in these patients were safe and effective, at least in the short term. Patients with rapid loss of motor function, lipomyelomeningocele, or split cord malformation seem to be at a higher risk of postsurgery deterioration. A follow-up period of many more years will be necessary to determine whether aggressive surgery is beneficial in the long term.

KEY WORDS • tethered cord syndrome • neurosurgery • spina bifida • spinal dysraphism • adult

TETHERED cord syndrome is a well-known manifestation of spina bifida occulta and can be a complication of surgically closed spina bifida aperta. Symptoms of TCS include back pain radiating to both buttocks and legs, muscle weakness, sensory deficit, loss of bladder/bowel control, and skeletal and foot deformities. Treatment is directed at prevention or reversal of progressive neurological symptoms. Patients with spinal dysraphism, either unrecognized or diagnosed in childhood, remain at a life-long risk for neurological deterioration. It has been acknowledged that symptomatic TCS can occur in adults as well as in children.^{11,14} In most studies on surgical intervention in TCS the surgeons treat children, and such studies have shown a beneficial effect and a low surgery-related morbidity rate.^{9,15} Some authors have even advocated a prophylactic treatment to prevent progressive neurological symptoms.¹⁶

Reports on surgical treatment of adult patients with TCS

Abbreviations used in this paper: CSF = cerebrospinal fluid; MR = magnetic resonance; SCM = split cord malformation; TCS = tethered cord syndrome.

are rare, and the results are difficult to compare.^{4,5,7,8,10,12,14} Analysis of these studies indicates an improvement in 40 to 80% of patients with surgery-related deterioration in approximately 8% of cases; however, these studies are retrospective in nature and conducted by the attending neurosurgeon(s), which causes a possible bias in the evaluation of the results. Because of this lack of reliable data, many doctors may be reluctant to refer these patients to a neurosurgical clinic, and when they do, significant progressive neurological deficits are usually present. To evaluate the risks of surgical treatment in adult patients with TCS, we studied the results of surgery in 57 adults in whom the neurological assessment was conducted in a standardized fashion by an independent neurologist.

Clinical Material and Methods

Patients Population

From January 1990 to December 1998, 196 patients underwent surgery for TCS. These patients were directly referred by neurologists to the neurosurgical department in

Utrecht. Of these cases, 139 patients were younger than 18 years of age. The remaining 57 adult patients, with a documented history of progressive neurological deficit were included in this study. There were 32 women and 25 men, who ranged in age from 19 to 75 years (mean age 41 years) at the time of surgery. The mean age at onset of symptoms was 30 years and at diagnosis of symptomatic TCS was 37 years. The diagnosis of an MR imaging–defined tethered cord was not exclusively defined by an abnormally low lying conus medullaris but was made when any structural tethering lesion that obstructed normal free movement of the spinal cord was present. As different types of operations—that is, operative strategies varying from relatively straightforward to very complex—are required for various causes of TCS, the following subgroups were defined according to their similar operative approach: 1) postrepair of myelomeningocele; 2) filum terminale lipoma and tight filum terminale; 3) lipomyelomeningocele and conus lipoma; and 4) SCM.

Patient Evaluation

All patients were evaluated in a standardized fashion before and after (range 1–4 weeks) surgery. Evaluation included an interview and a neurological examination that focused attention on the spine, lower extremities, and bladder and bowel function. Muscle strength was tested in eight muscles in both legs (gluteus, iliopsoas, quadriceps femoris, hamstrings, anterior tibial, extensor hallucis longus, peroneal, and gastrocnemial) using a Medical Research Council grading system. Summation of examination results could lead to a maximum score of 80.¹³ Disability was scored for each patient before and 6 months after surgery by using the modified Rankin Disability Scale.¹⁷ A urodynamic examination was performed preoperatively in most patients. Patients were seen by the same neurologist (N.C.N.) during follow-up visits at approximately 6 months and most patients also at 2 years.

Surgical Treatment

Surgery was performed in all patients by the same neurosurgeon (W.P.V.). Surgery consisted of complete untethering of the spinal cord, removal of tethering processes such as osseous spines in SCMs, and reduction of intramedullary lipomas. Care was taken to create a sac filled with CSF around the released conus medullaris to reduce the chances of the cord becoming retethered. Frequently, cadaveric dura mater or dural substitute was used to reconstruct the thecal sac. In complicated cases, closure of fascia and skin was performed by a plastic and reconstructive surgeon.

Data Analysis

The nonparametric Wilcoxon signed ranks test was used to determine differences in motor sum scores and Rankin scores between the pre- and postoperative status for the whole group and for the four defined subgroups. A probability value of less than 0.05 was considered to be significant.

Results

A summary of symptoms and signs at the time of

surgery is presented in Table 1. Twenty-one patients had undergone previous surgery for their tethered cord (12 primary closures of myelomeningocele and nine attempted untethering procedures), and 15 patients had undergone orthopedic procedures, including surgery for talipes cavus or scoliosis correction. The cause of tethering was diverse: lipoma of the filum terminale in 20 patients, postrepair myelomeningocele in 12, SCM in 12, lipomyelomeningocele in nine, conus lipoma in three, and tight filum terminale in one patient. Conus level, as assessed by MR imaging, was distributed as follows: T10–12 in two patients, L1–2 in eight, L3–4 in 15, L5–S1 in 11, and S2–5 in 21 patients. Additional anomalies that were discovered included dermoid cysts in three patients and syringohydromyelia in nine patients. A urodynamic examination was performed in 47 patients, and abnormal results were demonstrated in 33 cases, in which sphincter–detrusor dysynergia was usually found.

Direct Postoperative Period

Standardized measurement of muscle strength showed no change in 38 patients (67%) and improvement in 15 patients (26%) compared with preoperative scores (Fig. 1). Two patients experienced a slight decline in motor score. In an additional two (3.5%) significant deterioration occurred, leading to loss of ambulation. Both patients had experienced a rapid loss of motor function before surgery, requiring bilateral support when walking, and the occasional use of a wheelchair. All four patients in whom deterioration occurred postoperatively harbored either a lipomyelomeningocele (two patients) or an SCM (two patients). None of the patients who were neurologically intact preoperatively experienced postoperative neurological deficits.

Pain improved in 29 patients, was unchanged in 25, and deteriorated in three; gait improved in 23 patients, was unchanged in 30, and deteriorated in four; sensory function improved in three patients, was unchanged in 52, and deteriorated in two; and bladder/bowel function improved in nine patients, was unchanged in 48, and deteriorated in none.

TABLE 1
Summary of symptoms and signs at the time of surgery of
57 adult patients with TCS

Symptoms & Signs	No. of Patients (%)
back pain	42 (74)
leg pain	41 (72)
asymmetry	38 (67)
gait disturbance	30 (53)
weakness	25 (44)
paresthesia	31 (54)
bladder dysfunction	38 (67)
bowel dysfunction	22 (39)
impotency*	7 (28)
skin abnormality	42 (74)
foot deformity	41 (72)
scoliosis	38 (67)
leg atrophy	25 (44)
decreased motor function	40 (70)
asymmetry in motor function	39 (68)
decreased sensory function	40 (70)

* Present in men only (25 overall cases).

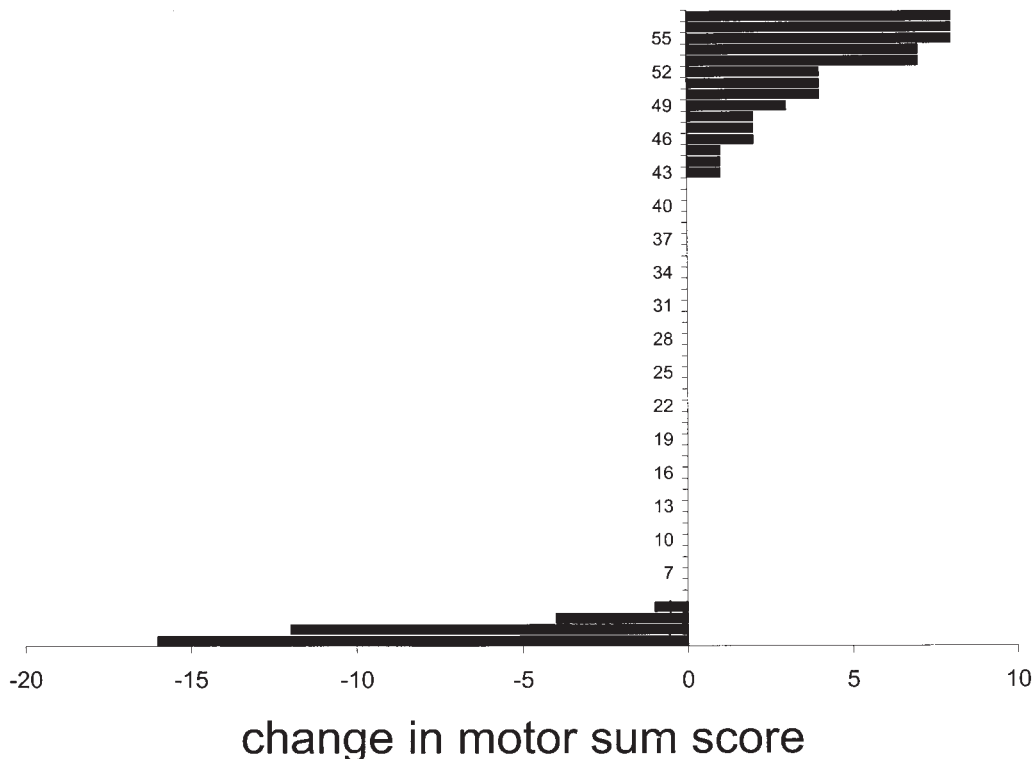


FIG. 1. Graph showing change in muscle strength, as measured in a standardized fashion by an independent neurologist, after surgical release of a tethered cord in 57 adult patients. Absolute motor sum scores are presented. The maximum sum score to be obtained was 80.

Surgery-related complications consisted of CSF leakage in seven cases (12%) and difficult wound healing in one (2%). All complications could be treated conservatively.

Six-Month Follow-Up Examination

Of 57 patients, 51 were examined 6 months after surgery. Pain had improved in 28 patients, was unchanged in 20, and deteriorated in three; gait remained improved in 17 patients, was unchanged in 30, and remained deteriorated in four; sensory function improved in five patients, was unchanged in 44, and remained deteriorated in two; bladder/bowel function remained improved in seven patients, was unchanged in 44, and deteriorated in none.

Two-Year Follow-Up Examination

Of 57 patients, 40 were available for follow up at 2 years. Pain was improved in 19, unchanged in 18, and deteriorated in three; gait was improved in 12, unchanged in 24, and deteriorated in four; sensory function was improved in six patients, unchanged in 32, and deteriorated in 2; bladder/bowel function was improved in six patients, unchanged in 33, and deteriorated in one.

Rankin Disability Scores

Preoperative Rankin Scale scores are presented in Table 2 for each defined subgroup. Postoperatively, a drop in Rankin score from 2 to 3 was observed in one patient

whereas 25 patients (44%) improved 1 (23 patients) or even 2 (two patients) points on the scale. This improvement was statistically significant ($p < 0.0001$). The improvement in Rankin score was not significant for patients with postrepair myelomeningocele ($p = 0.059$) but was for the other subgroups (filum terminale lipoma and tight filum terminale, $p = 0.038$; lipomyelomeningocele and conus lipoma, $p = 0.008$; SCM, $p = 0.046$).

The changes in motor sum score of all patients were not significant ($p = 0.069$) nor were they for subgroups. Remarkably, in all four patients in whom a new motor deficit developed postoperatively (two of which were significant deficits) there was no change in Rankin disability score.

Postrepair Myelomeningocele. Improvement in modified Rankin score was observed in three of 12 patients with myelomeningocele.

Filum Terminale Lipoma and Tight Filum Terminale. In 11 (52%) of these 21 patients improvement in the modified Rankin score was demonstrated. In one patient function deteriorated, as reflected by a drop of one Rankin score, whereas the motor sum score pre- and postoperatively showed a maximum of 80 points.

Lipomyelomeningocele and Conus Lipoma. Three patients with these lesions improved based on assessment with the modified Rankin Scale.

Split Cord Malformation. Improvement in the modified Rankin score was observed in eight (67%) of 12 patients with SCM.

TABLE 2
Summary of preoperative modified Rankin Disability Scale scores for each subgroup of patients

Modified Rankin Scale Score	Postrepair Myelomeningocele	Filum Terminale Lipoma	Lipomyelomeningocele	SCM
1	0	2	1	0
2	3	17	8	8
3	9	2	3	4
no. of patients	12	21	12	12

Discussion

In this study of the largest series of adult patients with TCS, we have shown, by means of independent, standardized neurological assessment, that surgical intervention for the release of the tethered spinal cord is safe and effective. In addition, the symptoms of pain, gait, sensory function, and of bladder/bowel function showed remarkable subjective improvement.

Preoperative Assessment

Even with the widespread availability of MR imaging, a long period between onset of (new) symptoms and final diagnosis of TCS is still common. In our study, a mean delay in diagnosis of 7 years was found. This delay might be explained by the rare frequency of this disorder in combination with the high prevalence of similar symptoms due to other clinical entities. Patients with signs and symptoms of a lumbar disc disease, for example, may only later turn out to suffer from a TCS.⁶ A high index of suspicion on the surgeon's part should reduce this delay in the future. In addition to a delay in diagnosis, we found a mean delay in surgical treatment of 4 years, which may be caused by a reluctance of physicians to refer these patients to a neurosurgical clinic or by a reluctance on the part of the consulted neurosurgeon to perform surgery, both for fear of surgery-induced neurological deterioration. We have shown that surgery-induced morbidity in general is very low in experienced hands and that neurologically intact patients fare best.

Extrapolation of Experience With Pediatric Cases

Most of our knowledge regarding diagnosis and treatment of TCS is based on experience in children. In children with tethering lesions, it has been demonstrated that appropriate surgery prevents neurological deterioration and leads to improvement of neurological symptoms.¹⁶ Pierre-Kahn, et al.,¹⁵ have shown that surgery is easy and safe when performed for treatment of lipomas of the filum but can be difficult and hazardous in cases of lipoma of the conus medullaris or complicated SCMs. Currently, the rate of surgery-induced neurological deficit is on the order of 3 to 12% when in the hands of experienced pediatric neurosurgeons.^{1,3,15} Surgery has been shown to improve all types of deficit, although the success of long-term surgery-related results does seem to diminish with time, depending on the anatomical type of the tethering lesion. Changes in bladder-sphincter function after untethering are usually transient, and a small group of children even seems to benefit

from untethering.² For all these reasons, aggressive and prophylactic surgery have been advocated.¹⁶

In adult patients with TCS, very few studies have been performed to address whether the benefits of surgery outweigh the risks. For this issue to be resolved, accurate assessment of the risk of surgery-induced neurological deterioration is essential before one can define whether aggressive surgery is beneficial in the long term. Systematic, independent assessment has not been reported. In most reports in the literature the authors have focused on the benefits of surgery, and the results are usually evaluated by the surgeon(s) who performed the operation.^{4,5,7,8,10,12,14} Pang and Wilberger¹⁴ have stated that a majority of patients were free of pain following surgery, although no follow-up period is mentioned. The reason for this positive outcome might be the fact that the authors included many patients with thickened filum, which is a relatively benign cause of tethering. Yamada, et al.,¹⁸ have reported improvement in pain and motor function in all patients in their series, but they only included those with a tethered cord caused by a fibrous or lipomatous filum terminale. Iskandar, et al.,¹⁰ excluding patients with postmyelomeningocele-related tethered cord, found improvement in pain status in over 80% of their patients. It should be noted, however, that they used clinic notes recorded by the physician instead of independent, objective measurement of symptoms and signs.

Muscle Strength and Disability Assessment

We studied the risk of surgery by objective measurement of muscle strength and assessment of disability pre- and postoperatively; these measurements were determined by an independent neurologist, and short and (relatively) long-term subjective symptoms were recorded. In terms of muscle strength only, the percentage of significant deterioration in our study was 3.5%. This risk was strongly related to the anatomy of tethering and the preoperative neurological condition of the patient. Surgery in patients with postrepair myelomeningocele and filum lipoma is relatively straightforward, even after previous attempts at surgical untethering, whereas SCM and lipomyelomeningocele can be extremely complicated to untether, especially when previous untethering attempts have been performed. The specific cases of deterioration that we encountered may be related to a combination of very complicated causes (lipomyelomeningocele and SCM), a rapid decline in motor function experienced shortly before operation, and an (unacceptable) long delay of surgery. Analysis of the surgery-related risk assessed by pre- and postoperative disability scales clearly showed that, even for technically challenging dysraphic disorders of the spine and spinal cord, surgery for symptomatic TCS is safe and effective, at least in the short term, in adults. Our results preclude any conclusions as to a possible beneficial effect in the long-term effect of surgical untethering procedures. A follow up of many more years will be necessary to determine whether aggressive surgery is beneficial in the long term and how many of these treated patients will return with recurrent symptoms.

The objective of our study was not to study the long-term effects of surgery but to assess accurately the risk of surgery in a population of patients with symptomatic TCS of diverse origins. For this purpose use of the Rankin

Adult tethered cord syndrome

Scale was quite sufficient, more so than objective measurement of motor sum scores.

Surgery-Related Complications

The risk of general complications is fairly constant among different studies in adult patients with TCS.^{4,8,10,12,14} The mortality rate is very low: just one death was reported due to meningitis secondary to a CSF leak.¹⁴ Infections and subcutaneous pseudomeningoceles vary from 11 to 36%. Our morbidity rate of 14% lies well within the lower limit of this range.

Conclusions

It remains to be proven whether aggressive and prophylactic surgery for TCS should be advocated in patients older than 18 years of age, as it is in children and young adults. However, based on our study of 57 adult patients with TCS, we conclude that surgical untethering performed by an experienced neurosurgeon is a safe and effective procedure, which should preferably be undertaken before serious neurological dysfunction occurs. How to distinguish the long-term effects of surgery from deterioration caused by retethering or ongoing natural history remains to be studied, but such distinction may prove to be nearly impossible to define. A follow up of many more years will be necessary.

References

1. Albright AL, Pollack IF, Adelson PD, et al: Outcome data and analysis in pediatric neurosurgery. **Neurosurgery** **45**:101–106, 1999
2. Boemers TM, van Gool JD, de Jong TP: Tethered spinal cord: the effect of neurosurgery on the lower urinary tract and male sexual function. **Br J Urol** **76**:747–751, 1995
3. Byrne RW, Hayes EA, George TM, et al: Operative resection of 100 spinal lipomas in infants less than 1 year of age. **Pediatr Neurosurg** **23**:182–187, 1995
4. Filler AG, Britton JA, Uttley D, et al: Adult postrepair myelomeningocele and tethered cord syndrome: good surgical outcome after abrupt neurological decline. **Br J Neurosurg** **9**:659–666, 1995
5. Giddens JL, Radomski SB, Hirshberg ED, et al: Urodynamic

- findings in adults with the tethered cord syndrome. **J Urol** **161**:1249–1254, 1999
6. Gokay H, Barlas O, Hepgul KT, et al: Tethered cord in the adult mimicking the lumbar disc syndrome: report of two cases. **Surg Neurol** **39**:440–442, 1993
7. Gupta SK, Khosla VK, Sharma BS, et al: Tethered cord syndrome in adults. **Surg Neurol** **52**:362–370, 1999
8. Guyotat J, Bret P, Jouanneau E, et al: [Tethered cord syndrome in adults]. **Neurochirurgie** **44**:75–82, 1998 (Fr)
9. Hoffman HJ, Hendrick EB, Humphreys RP: The tethered spinal cord: its protean manifestations, diagnosis and surgical correction. **Childs Brain** **2**:145–155, 1976
10. Iskandar BJ, Fulmer BB, Hadley MN, et al: Congenital tethered spinal cord syndrome in adults. **J Neurosurg** **88**:958–961, 1998
11. Kaplan JO, Quencer RM: The occult tethered conus syndrome in the adult. **Radiology** **137**:387–391, 1980
12. Klekamp J, Raimondi AJ, Samii M: Occult dysraphism in adulthood: clinical course and management. **Childs Nerv Syst** **10**:312–320, 1994
13. Notermans NC, Wokke JH, Lokhorst HM, et al: Polyneuropathy associated with monoclonal gammopathy of undetermined significance. A prospective study of the prognostic value of clinical and laboratory abnormalities. **Brain** **117**:1385–1393, 1994
14. Pang D, Wilberger JE Jr: Tethered cord syndrome in adults. **J Neurosurg** **57**:32–47, 1982
15. Pierre-Kahn A, Zerah M, Renier D, et al: Congenital lumbosacral lipomas. **Childs Nerv Syst** **13**:298–335, 1997
16. Reigel DH, McLone DG: Tethered spinal cord, in Cheek WR, Marlin AE, McLone DG, et al (eds): **Pediatric Neurosurgery: Surgery of the Developing Nervous System**. Philadelphia: WB Saunders, 1994, pp 77–95
17. van Swieten JC, Koudstaal PJ, Visser MC, et al: Interobserver agreement for the assessment of handicap in stroke patients. **Stroke** **19**:604–607, 1988
18. Yamada S, Iacono RP, Douglas CC, et al: Tethered cord syndrome in adults, in Yamada S (ed): **Tethered Cord Syndrome**. Chicago: American Association of Neurological Surgeons, 1996, pp 149–165

Manuscript received June 16, 2000.

Accepted in final form October 23, 2000.

Address reprint requests to: W. Peter Vandertop, M.D., Ph.D., Department of Neurosurgery, University Hospital Vrije Universiteit, P.O. Box 7057, NL-1007 MB Amsterdam, The Netherlands. email: wp.vandertop@azvu.nl.